



PATIENT

GG Roberts

SPECIES

Canine

BREED

Chihuahua

SEX

Female Spayed

AGE

8 years

WEIGHT

7.4lbs

INTERPRETED BY

Maggie Machen Lamy,
DVM, DACVIM
(Cardiology)

IMAGING PERFORMED BY

Dana Alterman,
RDCS, LVT

HOSPITAL NAME

Eubank Animal Clinic

REFERRING VET

Dr. Hood

INVOICE

31540

DATE

6/26/23

PRESENTING CLINICAL SIGNS

History: Coughing. Increased RR and exercise intolerance. Suspected pulmonary hypertension secondary to lower airway disease.

-Current medications: Prednisolone 0.5mg/kg PO BID.

-Abnormal PE/Chem/CBC/UA Results: Increased ALT/AST.

RADIOGRAPHIC FINDINGS *NOTE: Images submitted for supplemental cardiac information only. Mild right-sided cardiomegaly. No obvious evidence of CHF.

ELECTROCARDIOGRAPHIC FINDINGS

A six lead ECG is available at 25mm/s; 10mm/mV. The average heart rate is 160bpm (range 150-172bpm). The rhythm is sinus in origin, with a p for every QRS complex and vice versa. The P wave morphology is positive with a normal dimension. Normal PR. The QRS morphology is positive with normal dimension. MEA is normal. No ectopic beats, pauses or dysrhythmias observed.

ECG diagnosis: Normal sinus tachycardia.

ECHOCARDIOGRAM FINDINGS

2D, m-mode, color flow and doppler imaging is available. Mild thickening of mitral valve leaflets with no obvious prolapse into the left atrial lumen. No mitral regurgitation with no left atrial dilation. Decreased LV diameter with adequate myocardial function. The tricuspid valve appears mildly thickened with mild tricuspid regurgitation. Mild right atrial enlargement; moderate right ventricular hypertrophy. TR velocity consistent with severe pulmonary hypertension. The pulmonic and aortic valves are normal in morphology and mobility. Main PA and branch dilation. Trace pulmonic and no aortic insufficiency. No pericardial or pleural effusion noted. No cardiac tumors observed.

CARDIAC CHART

CANINE CARDIAC PARAMETERS	MR VMAX (m/s)	TR VMAX (m/s)	LA/AO (Boon method)	LA/AO (Heart Base; Swe)	FS (%)	EF (%)	EPSS (cm)
NORMAL PARAMETER	4.5-5.5	<2.7	1.3	<1.6	28-40	40-100	<0.6
PATIENT	NA	4.6	1.0	1.2	53	86	0.2
CANINE CARDIAC PARAMETERS	HR (BPM)	AV VMAX (m/s)	PV MAX (m/s)	BODY WEIGHT (kg)	LA 2D short axis Base view (cm)	LVIDd Avg; 2D and m-mode short axis (cm)	LVIDs Avg; 2D and m-mode short axis (cm)
NORMAL PARAMETER	50-100	0.7-1.7	0.7-1.6	BELOW	BELOW	BELOW	BELOW
PATIENT	NM	0.94	0.6	3.4	1.5	1.5	0.7
*Normal chamber parameters expressed as a mean value (SD)				3	1.27 (5.3)	2.46 (2.46)	1.36 (5.5)
BODY WEIGHT DEPENDENT PARAMETERS				5	1.40 (4.5)	2.74 (5.2)	1.60 (4.7)
*Note: All measurements based upon multi-modal images and methods. An average value is reported.				10	1.50 (3.8)	3.27 (3.5)	2.06 (3.1)
				15	1.83 (2.0)	3.71 (2.4)	2.43 (2.1)
				20	2.02 (1.9)	4.14 (2.2)	2.80 (2.0)
				25	2.18 (2.4)	4.48 (2.9)	3.10 (2.5)
				30	2.33 (3.3)	4.83 (3.9)	3.39 (3.4)
				35	2.48 (4.3)	5.17 (5.0)	3.69 (4.5)

Adapted from June Boon, Veterinary Echocardiography, 1998
Rishniw M and Hollis NE, J Vet Intern Med 2000; 14:429-435
Hansson et al, Vet Rad and Ultrasound 2002



PATIENT

GG Roberts

Bonagura et al. Echocardiography: principles of interpretation, Vet Clin North Am 15:1177, 1995	40	2.62 (5.2)	5.48 (6.1)	3.96 (5.4)
	50	2.88 (7.1)	6.07 (8.3)	4.46 (7.4)

SPECIES

Canine

BREED

Chihuahua

SEX

Female Spayed

AGE

8 years

WEIGHT

7.4lbs

INTERPRETED BY

Maggie Machen Lamy,
DVM, DACVIM
(Cardiology)

IMAGING PERFORMED BY

Dana Alterman,
RDCS, LVT

HOSPITAL NAME

Eubank Animal Clinic

REFERRING VET

Dr. Hood

INVOICE

31540

DATE

6/26/23

INTERPRETATION OF THE FINDINGS & FURTHER RECOMMENDATIONS

Severe pulmonary hypertension (PAH) is present, as evidenced by an elevated TR velocity and right heart enlargement. The estimated systolic pulmonary arterial pressure is >90mmHg, with normal being <25mmHg. This is causing significant hypertrophy and dilation of the right heart (indicating severe right-heart pressure overload). Clinical signs of weakness, heavy breathing, cyanosis, and syncope are attributed to severe PAH. No additional issues are identified. The ECG is unremarkable with a normal sinus rhythm.

The underlying genesis of PAH is poorly understood in cases other than heartworm infestation, though it occurs with increased frequency in a variety of forms of chronic lung disease and in patients with idiopathic pulmonary fibrosis. If not performed, a heartworm antigen test is recommended. Given the chronic cough and degree of the disease seen here, COPD/chronic bronchitis and/or primary PF as an underlying cause with an acute secondary exacerbating insult (infectious or inflammatory) is suspected. Patients with this degree of PAH and pulmonary disease can develop right-sided congestive heart failure (ascites), debilitating cyanosis, labored breathing and exertional syncope if poorly controlled.

If there has been an acute increase in symptom, recommend coverage with a board-spectrum pulmonary antibiotic as below to treat any infectious component. Additionally, vasodilation using Sildenafil is recommended. No indication for Lasix therapy as diuretics can actually further reduce preload in cases of debilitating PAH and worsen clinical signs. Depending on severity of symptom, can also consider anti-inflammatory steroids, bronchodilators, etc. The best way to slow progression in PAH is adequate cough control and cannot be stressed enough. Long term prognosis is poor, with risk for acute respiratory compromise, syncope and/or sudden death going forward.

Omega fatty acid supplementation (anti-inflammatory) may be of some long-term benefit. Monitor for worsening of labored breathing, exercise intolerance or collapse episodes.

Once on the medications for 3-5 days, anesthetic risk remains moderately elevated. Patients with respiratory disease are at risk for hypoxia both during and after the event, and pre-oxygenating for 5-10 minutes is recommended. Additionally, recovery in an oxygen chamber is ideal. Cardiac protective drug choices (opioid/benzodiazepine premedication, Propofol or alfaxalone induction, iso or sevo gas) are recommended. Monitor for arrhythmias, hypotension, and hypoxia both intra and post-operatively and intervene as necessary. Judicious IV fluid rates are recommended to avoid fluid overload. Avoid heart rate stimulating drugs such as atropine unless clinically indicated.

PLAN

If indicated, consider broad spectrum pulmonary antibiotics (Enrofloxacin 5-7mg/kg PO q24h for 10 days). Institute sildenafil (Viagra) 1-2mg/kg PO q8h. Bronchodilators, steroids, etc. as needed.

Recommend recheck echocardiogram in 6 months to reassess pulmonary pressures, sooner if any development of clinical signs.



PATIENT

GG Roberts

SPECIES

Canine

BREED

Chihuahua

SEX

Female Spayed

AGE

8 years

WEIGHT

7.4lbs

INTERPRETED BY

Maggie Machen Lamy,
DVM, DACVIM
(Cardiology)

IMAGING PERFORMED BY

Dana Alterman,
RDCS, LVT

HOSPITAL NAME

Eubank Animal Clinic

REFERRING VET

Dr. Hood

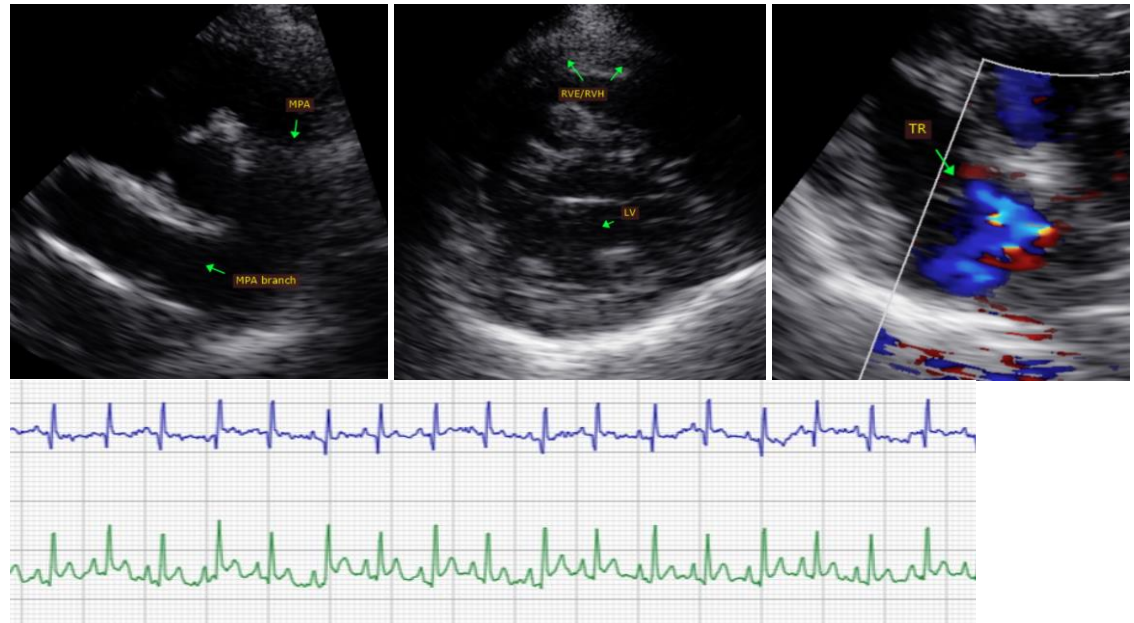
INVOICE

31540

DATE

6/26/23

IMAGES



The information and recommendations provided are based on the images presented by the referring veterinarian. No evaluation can be communicated regarding pathology that was not visible in the image/video clips provided.

Thank you for this referral. This report was generated using transcription software, and minor dictation errors may be present. If the clinical or image interpretation does not parallel your findings or if I can be of any further assistance, please contact me.

Maggie Machen Lamy, DVM
Diplomate of the American College of Veterinary Internal Medicine (Cardiology)
info@sonopath.com